PENSOFT

CAUCASIANA
Journal on the biodiversity of the Caucasus and the adjacent regions

Two-headed parthenogenetic lizard embryo from southern Georgia

Giorgi Iankoshvili[1], Nikoloz Tsikolia[2], Natia Barateli[1], Mariam Gabelaia[3], Armen Seropian[1], David Tarkhnishvili[1]

1 *Institute of Ecology, Ilia State University, Tbilisi, Georgia*
2 *Anatomie und Embryologie, Zentrum Anatomie, Universitätsmedizin Göttingen, Göttingen, Germany*
3 *Museum A. Koenig, Leibniz Institute for the Analysis of Biodiversity Change (LIB), Bonn, Germany*

http://zoobank.org/B4915667-4B45-4C3E-B85C-2E971400D8E2

Corresponding author: Author Name (david_tarkhnishvili@iliauni.edu.ge)

Academic editor: Levan Mumladze ♦ **Received:** 21 August 2023 ♦ **Accepted:** 30 October 2023 ♦ **Published:** 20 November 2023

Abstract

Visual inspection of several embryos of the parthenogenetic lizard *Darevskia armeniaca* revealed the presence of an embryo with axial bifurcation ("two-headed") on the stage of pigmented eyes and plate-like limb buds with a distinct border at the edges. This is the third recorded case of axial bifurcation in *D. armeniaca*, although two previous cases were mentioned without further discussion. Here the bicephalic embryo is described in detail and the potential reasons are discussed. The analysis of the literature on axial bifurcation in lacertids suggests that this type of developmental disorder may be particularly common in this parthenogenetic form. Hybridization may cause multiple developmental disorders, including incomplete separation of twin embryos; all parthenogenetic *Darevskia* have a hybrid origin, and this may cause the disorders rather than parthenogenetic reproduction by itself. The hypothesis needs further study with more representative samples of parthenogenetic and sexually reproducing *Darevskia*.

Key words

Axial bifurcation, hybridogenous parthenogenesis, Squamata, *Darevskia*

Introduction

Axial bifurcation is an extreme case of developmental instability, which, in turn, may stem from genetic disorders and/or environmental effects (Møller 1997). It may result from the incomplete separation of identical twins or duplication of the notochord (Wu et al. 2002). Axial bifurcation remains a reasonably rare phenomenon, though hundreds of bicephalic organisms have been recorded since ancient times. Bicephalic individuals are recorded for all vertebrate groups, including lampreys (Hanson 1985; Suzuki 2016), sharks (Goto et al. 1981; Wagner et al. 2013), bony fish (Gudger 1938; Jezierska et al. 2000), salamanders (Fernández-Álvarez et al. 2011; Pereira and Rocha 2004; Au et al., 2020), frogs (McFadden et al. 2011), turtles (Diong et al. 2003; Palmieri et al. 2012; Sönmez et al. 2017; Ingle et al. 2021), crocodilians (Elsey and Stelly 2018), lizards (Pleitcha 1968; Payen 1995; Spadolla and Insacco 2009; Ruiz-Villanueva et al. 2018; Di Marzio et al. 2023) as well as mammals (Wu et al. 2002; Ibrahim 2021), being relatively common in snakes (Cunningham 1937; Wallach 2007).

Bicephaly prevalence in squamates is taxon-specific. Wallach (2018) summarized the information on bicephaly in snakes available by that date. He accounted for 1850 records of axial duplication, including 542 cases in colubrids, 335 in natricids, 266 in viperids, and only 13 in elapids. In other squamates, axial bifurcation is relatively rare. Di Marzio et al. (2023) in their review list 49 reports of conjoined twins

Copyright *Iankoshvili et al.* This is an open access article distributed under the terms of the Creative Commons Attribution License (CC BY 4.0), which permits unrestricted use, distribution, and reproduction in any medium, provided the original author and source are credited.

in different lizard families, including 14 cases in lacertids. Two of these cases belong to the parthenogenetic form, *Darevskia armeniaca* (Darevsky 1966; Payen 1995). Other lacertids with recorded bicephaly are the sand lizard (*Lacerta agilis*; 3 cases), green lizard (*Lacerta viridis*; 2 cases), wall lizard (*Podarcis muralis*; 3 cases), Italian wall lizard (*Podarcis siculus*; single case), jeweled lizard (*Timon lepidus*; single case), and viviparous lizard (*Zootoca vivipara*; 2 cases). Below, we describe a third case of axial bifurcation in the parthenogenetic *D. armeniaca*, now recorded in an embryonic stage. The third finding of a bicephalic specimen in the same parthenogenetic form, which is not widespread or particularly numerous, may indicate that this anomaly may reflect a predisposition of this form to developmental anomalies; therefore, we found it worth publishing in a separate paper.

Materials and methods

Sixteen individuals of *Darevskia armeniaca* were caught during the reproductive season (July 2023) near Saghamo Lake in southern Georgia (N43.73°, E41.29°; elevation 2015 m. a.s.l.; mountain steppe with rocky outcrops) and taken into the laboratory for observation on the egg development. All females deposited eggs between June 23 and July 7. The eggs were fixed in a 4% paraformaldehyde solution 1–17 days after deposition. Embryos were observed under a Zeiss Stemi 508 stereo microscope with an 8:1 zoom and a Zeiss Apo 1.5x FWD 53 mm front lens attached. Images of the embryos (Fig. 1) were taken using a Canon EOS 60D camera with a Canon MP-E 65mm f/2.8 1–5x Macro Photo Lens mounted on a Novoflex Castel-L Focusing Rack. Digital images were prepared using Zerene Stacker image stacking software and Adobe Photoshop CS6. In 2021-2022, egg clutches of different *Darevskia* species were obtained in the laboratory (Barateli et al. 2022).

The numbers of hatched juveniles we add to the published data in order to infer the rough frequency of hatchlings with developmental anomalies (Table 1). Embryos were staged according to Wise et al. (2009), whereas the decisive criterion was the development of limbs.

Results and discussion

The bicephalic embryo was found in an egg fixed 17 days after deposition. The other 11 eggs of *Darevskia armeniaca* and 3 eggs of *Darevskia mixta* were fixed in 2 days after deposition; normally developing embryos were present. The embryo had two heads, two long necks, two pairs of forelimb buds, and a single body and tail; hence, it belonged to the category proarchodichotomous, according to Smith and Pérez-Higareda (1987). These categories were developed for snakes with axial bifurcation but appear to be applicable to other squamates. In snakes, this category of axial bifurcation is rare and comprises only 4.2% of the studied cases. Unfortunately, comparable information for lacertids is scarce. Inacco and Spadolla (2009) described a newborn *Podarcis sicula* with two pairs of forelimbs and two heads, similar to the embryo described here. Payen (1995) and González (2018) described a hatched prodichotomous *Zootoca vivipara*.

The overall morphology of the bicephalic embryo displayed signs of degradation, with poorly differentiated oedematous eyes with patchy pigmentation and abnormal surface ectoderm. The bicephalic embryo displayed limb features of stage 30: autopodium with apical ectodermal ridge, whereas normally developing embryos fixed from day 13 after egg deposition displayed three distinct limb segments with beginning digit condensation, hence matching stages 32-34.

The finding of the bicephalic embryo in a lizard egg is a rare event. So far, only 49 conjoined twins of lizards were found, including 11 bicephalic or conjoined twins in lacertids (Di Marzio et al. 2023). This is strikingly less than the cases of bicephalic individuals in snakes (Wallach 2007, 2018). Different from the bicephalic snakes, which survive

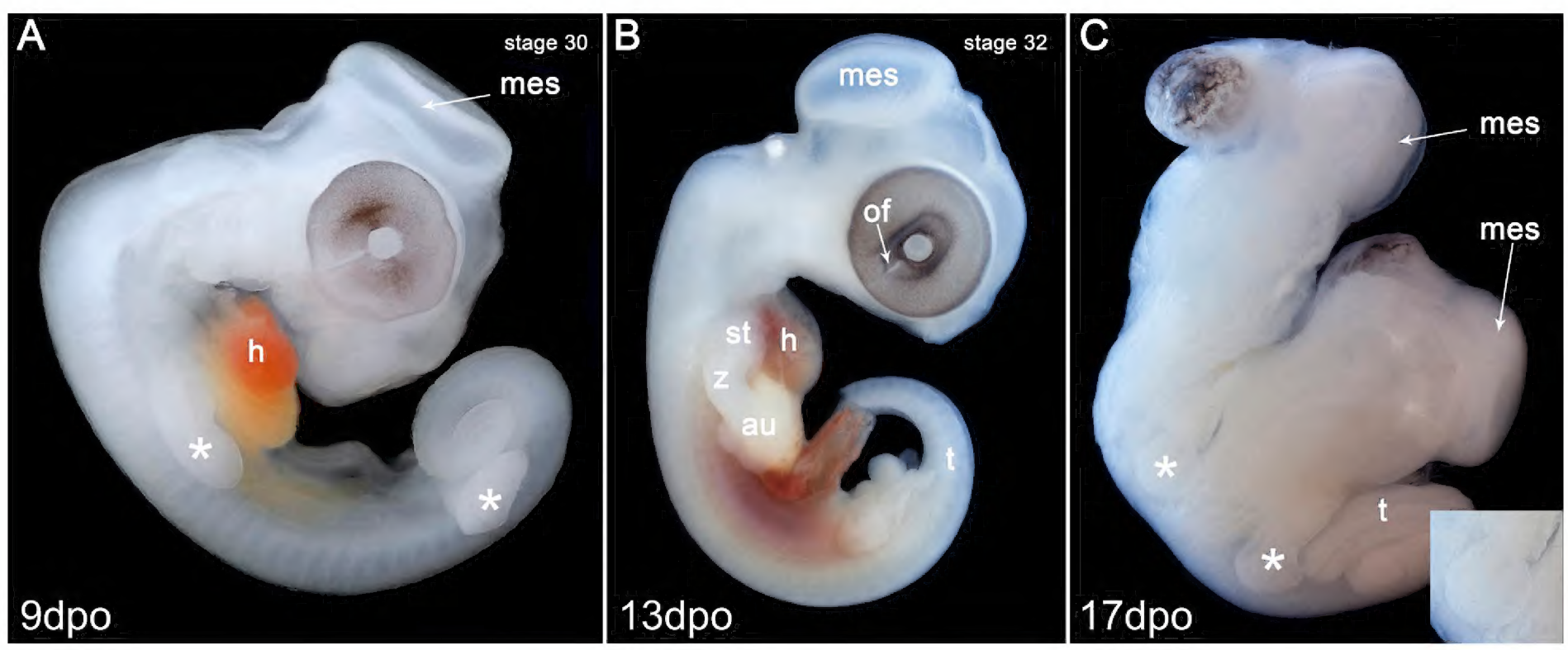

Figure 1. Lateral views of normally developed embryos (**A**, **B**) and dorsolateral view of a bicephalic embryo (**C**). Inset in C – details of limb morphology. Note differentiated eye primordia in A and B with an evenly pigmented retina and centrally located lens primordia. dpo – days post oviposition, st – stylopodium, z – zeugopodium, au – autopodium, mes – mesencephalon, of – optical fissure, asterisk – limb, h – heart, t – tail, AER - apical ectodermal ridge.

Table 1. The number of juveniles of *Darevskia* hatched in captivity that are reported by different authors and from our observations (Barateli and Iankoshvili, unpublished).

Species	Number of hatched individuals	Source
*D. armeniaca**	5	Darevsky 1966
D. valentini	3	Darevsky 1966
*D. rostombekowi**	3	Darevsky 1966
D. raddei	4	Darevsky 1966
*D. dahli**	4	Darevsky 1966
D. caspica	16	Kidov et al. 2022
D. saxicola	46	Kidov et al. 2021
D. pontica	28	Kidov 2018
*D. unisexualis**	168	Badayeva 2008
*D. armeniaca**	147	Badayeva 2008
D. alpina	7	Kidov et al. 2011
D. caucasica	1	Kidov et al. 2011
D. derjugini	11	Kidov et al. 2014
D. chlorogaster	10	Kidov et al. 2019
D. portschinskii	2	Our data
D. dahli	5	Our data
D. obscura	3	Our data
D. valentini	18	Our data
D. armeniaca	35	Our data
D. derjugini	1	Our data

* parthenogenetic forms

for years in 16% of the recorded cases (Wallach, 2018), there are no documented cases of survived conjoined twins in lizards, including lacertids (Di Marzio et al. 2023); this may be the reason why bicephaly in lizards is recorded as much rarer than in snakes. The embryo described in this paper, obviously, would die before hatching.

Even more interesting is that this is the third recorded bicephaly in a parthenogenetic species, *D. armeniaca*. This species, although relatively common in its natural habitats, has a very limited range and is observed by scientists and amateur herpetologists as much rarer than the species widespread in Europe, such as sand lizard or viviparous lizard. This drives us to the hypothesis that some specific features of *D. armeniaca* tend to develop twins, including conjoined twins, more commonly than most other lizard species. Is this a common feature of all Caucasian rock lizards of the genus *Darevskia*, all hybridogenous parthenogens from this genus, or specifically of *D. armeniaca*? For insight into this question, we summarized the recorded data on captive breeding of different rock lizard species. Lizards from this genus are relatively commonly bred in captivity for research purposes and kept in terraria. Unfortunately, most of the breeders do not report the number of hatched juveniles; however, there are only two reports of bicephalic individuals (see above). The number of juveniles hatched in captivity is shown in Table 1. Altogether, there are 517 recorded cases of captive hatching; however, judging from the reports of captive breeding, we can suppose there are several times more. More than one-third of those are *D. armeniaca*, and only for this parthenogenetic form are three cases of bicephalism (including that described in this paper) reported, which is 1.6% of all described juveniles hatched or developed in captivity.

This is a substantial proportion of bicephalic individuals, and it might be related to the specific developmental features of *D. armeniaca*. Unfortunately, all cases described in Table 1 are due to hatched juveniles, and potentially, the proportion of embryos with axial bifurcation may be substantially higher than such embryos that reach the hatching stage. However, two other cases of bicephaly in *D. armeniaca* are described for hatched juveniles, which is also remarkable.

Among the 11 potential reasons for axial bifurcation, Wallach (2007, 2018) lists inbreeding depression from small population gene pools and hybridization, as well as different environmental impacts. Since lizards are paraphyletic with respect to snakes (Simões and Pyron, 2021), this list is obviously applicable to other squamates. The natural habitats of *D. armeniaca*, including the location from which the mother of the bicephalic embryo described here was collected, lay in a natural setting (mountain steppe) on an elevation over 2,000 m and were not densely populated. Consequently, potential environmental reasons such as excessive pollution or radiation should rather be ruled out, and the genetic factors specific to this species are the most likely reasons.

Hybridization is a significant potential reason for axial bifurcation in reptiles. Indeed, Ball (1995) showed that crossing between two species of milk snakes (*Lampropeltis*) may produce offspring with axial bifurcation (Ball 1995; Wallach 2007). The backcross of a hybrid elapid snake, *Acantophis*, also produced a two-headed offspring (Maryan 2001).

All *Darevskia* parthenogens have hybrid origins (Murphy, 2000; Tarkhnishvili et al., 2020) and represent hybrid clones. This may be a potential reason for the relatively common axial bifurcation in these species. Remarkably, it appears that *D. armeniaca*, most likely, combines in its genome parts of the genome of three rather than two bisexual parental species: *D. mixta*, *D. valentini*, and *D. portschinskii* (Tarkhnishvili et al. 2021). This might cause the presence of multiple incompatible fragments in the genome of this species, causing not only the loss of sexual reproduction but other potential developmental problems. Notably, the parthenogens gradually return to a homozygous state of individual loci, including those where deleterious alleles may present as a result of a process of gene inversion (Tarkhnishvili et al. 2021).

At the moment, this remains a hypothesis because, different from the previous cases, bicephalic embryos may be more common in all lacertid species than the successful hatching of two-headed individuals. To validate our hypothesis, representative samples of the developing prehatched embryos should be analyzed in different species of sexually reproducing and parthenogenetic lizards, which is the matter of the ensuing study.

Acknowledgements

The project on which this study is based was funded by the Federal Ministry of Education and Research of Germany (BMBF) under grant number 01DK20014A. The responsibility for the content of this publication lies with the authors.

References

Au MFF, Shen J, Martelli P, Lau A (2020) First record of bicephaly in *Paramesotriton hongkongensis* (Myers and Leviton, 1962) (Caudata: Salamandridae). Herpetology Notes 13: 831–833.

Badaeva TN (2008) Study of the structural organization and polymorphism of microsatellite loci in the parthenogenetic lizard *Darevskia unisexualis*. Abstract of a candidate's dissertation for the degree of candidate of biological sciences. Institution of the Russian Academy of Sciences, Institute of Biology, Moscow, Russia. [in Russian]

Ball JC (1995) Axial bifurcation. Case study: a two-headed yellow rat snake. Reptile & Amphibian Magazine 32: 36–43.

Cunningham B (1937) Axial ifurcation in erpents: an historical survey of serpent monsters having part of the axial skeleton duplicated. Duke University Press, Durham, North Carolina, USA, 117 pp.

Darevsky IS (1966) Natural parthenogenesis in a polymorphic group of Caucasian rock lizards related to *Lacerta saxicola* Eversmann. Journal of the Ohio Herpetological Society 30: 115–152. https://doi.org/10.2307/1562588

Di Marzio A, Birbele E, Puchades L, Lazdiņš A (2023) A review of twinning in lizards and a report of veiled chameleon (*Chamaeleo calyptratus*) twin births. Herpetology Notes 16: 471–476.

Diong CH, Tan LKA, Leh CMU (2003) Axial bifurcation in a bicephalic *Chelonia mydas* embryo. Chelonian Conservation and Biology 4(3): 725–727.

Fernández-Álvarez FÁ, Recuero E, Martinez-Solano I, Buckley D (2011) First record of bicephaly in *Lissotriton boscai* (Amphibia, Caudata, Salamandridae). North-Western Journal of Zoology 7(1): 161–163.

Barateli N, Tarkhnishvili D, Iankoshvili G, Kokiashvili L (2022) Reproductive effort of unisexual and bisexual rock lizards (genus *Darevskia*). Zoologischer Anzeiger 301: 196–204. https://doi.org/10.1016/j.jcz.2022.11.002

Elsey RM, Stelly VM (2018) *Alligator mississippiensis* (American Alligator). Bicephaly. Herpetological Review 49: 738–739.

González JO (2018) Primer caso de bicefalismo en" *Zootoca vivipara*" en España. Boletín de la Asociación Herpetológica Española 29(2): 32–35.

Goto M, Taniuchi T, Kuga N, Iwata M (1981) Four Dicephalous Specimens of the Blue Shark, *Prionace glauca*, from Japan. Japanese Journal of Ichthyology 28(2): 157–165. https://doi.org/10.11369/JJI1950.28.157

Gudger EW (1938) Ten two-headed trouts from 32 mm to 203 mm long—the record size. Journal of the Elisha Mitchell Scientific Society 54(2): 205–233.

Hanson LH (1985) Observations on twinning in the sea lamprey (*Petromyzon marinus*) in the laboratory. Journal of Great Lakes Research 11(4): 549–551. https://doi.org/10.1016/S0380-1330(85)71799-6

Ibrahim IM (2021) Dicephalus in Hybrid Saanin Goat in Sudan-Case Report. Datess, 1(1): 101.

Ingle DN, Meredith TL, Perrault JR, Wyneken J (2021) Two heads are not always better than one: Craniofacial and axial bifurcation in cheloniid embryos and hatchlings (*Chelonia mydas* and *Caretta caretta*). Journal of Morphology 282(8): 1233–1244. https://doi.org/10.1002/jmor.21366

Insacco G, Spadola F (2009) Newborn dicephalic *Podarcis sicula*. Acta Herpetologica 4(1): 99–101.

Jezierska B, Lugowska K, Witeska M, Sarnowski P (2000) Malformations of newly hatched common carp larvae. Electronic Journal of Polish Agricultural Universities 3(2): 1–10.

Kidov AA (2018) On the Reproductive Biology of the Hyrcanian Meadow Lizard, *Darevskia praticola hyrcanica* (Lacertidae, Reptilia). Current Studies in Herpetology 18(3/4): 118–124. [in Russian] https://doi.org/10.18500/1814-6090-2018-18-3-4-118-124

Kidov AA (2021) Reproductive Biology of the Rock Lizard (*Darevskia saxicola*, Reptilia, Lacertidae). Biology Bulletin 48: 1314–1318. https://doi.org/10.1134/S106235902108015X

Kidov AA, Ivanov AA, Erashkin VO, Kondratova TE (2022) Captive breeding of the Caspian lizard (*Darevskia caspica*) (Reptilia, Lacertidae). Current Studies in Herpetology 22: 131–136. [in Russian] https://doi.org/10.18500/1814-6090-2022-22-3-4-131-136

Kidov AA, Ivanov AA, Kondratova TE, Stolyarova EA, Nemyko EA (2019) On repeated oviposition in green-bellied lizards of the *Darevskia* (*chlorogaster*) complex (Reptilia, Lacertidae). Current Studies of Herpetology 19(3/4): 153–159. [in Russian] https://doi.org/10.18500/1814-6090-2019-19-3-4-15

Kidov AA, Kovrina EG, Timoshina AL, Baksheyeva AA, Matushkina KA, Blinova SA, Afrin KA (2014) Breeding of the forest Artvin lizard, *Darevskia derjugini sylvatica* (Bartenjev et Rjesnikowa, 1931) in the valley of the Malaya Laba River (Northwestern Caucasus). Current Studies of Herpetology 14(3/4): 103–109. [in Russian]

Kidov AA, Timoshina AL, Matushkina KA, Pykhov SG, Livadina LV, Zhirimes VG (2011) Materials for investigation of Caucasian Lacertid lizards (Reptilia, Sauria, Squamata: Lacertidae). Scientific Research in Zoological Parks 27: 100–113.

Maryan B (2001) A note on a bicephalic death adder. Herpetofauna 31: 73–73.

McFadden M, Harlow P, Hunter D (2011) Bicephaly in the anuran *Pseudophryne pengilleyi*. Herpetological Bulletin 116: 25-26.

Møller AP (1997) Developmental stability and fitness: A review. The American Naturalist 149: 916–932. https://doi.org/10.1086/286030

Murphy RW, Fu J, Macculloch RD, Darevsky IS, Kupriyanova LA (2000) A fine line between sex and unisexuality: the phylogenetic constraints on parthenogenesis in lacertid lizards. Zoological Journal of the Linnean Society 130: 527–549. https://doi.org/10.1111/j.1096-3642.2000.tb02200.x

Palmieri C, Selleri P, Di Girolamo N, Montani A, Della Salda L (2012) Multiple congenital malformations in a dicephalic Spur-thighed Tortoise (*Testudo graeca ibera*). Journal of Comparative Pathology 149(2–3): 368–371. https://doi.org/10.1016/j.jcpa.2012.11.244

Payen S (1995) Axial duplication in lizards. Herpetopathologia 2: 171–180.

Pereira R, Rocha S (2004) *Chioglossa lusitanica* (Golden-striped Salamander) Dicephalic larva. Herpetological Bulletin 87: 29–30.

Pleticha P (1968) Micro-anatomical analysis of congenital head duplication of a lizard (*Lacerta agilis* L.). Vestnik Ceskoslovenske Spolecnosti Zoologicke 32: 232–236.

Ruiz-Villanueva K, Piedrasanta-López J, Ariano-Sánchez D (2018). Bicephaly in *Gonatodes albogularis* (Squamata: Sphaerodactylidae). Canadian Field-Naturalist 125: 359–362.

Simões TR, Pyron RA (2021). The squamate tree of life. Bulletin of the Museum of Comparative Zoology 163(2): 47–95. https://doi.org/10.3099/0027-4100-163.2.47

Smith HM, Pérez-Higareda G (1987) The literature on somatodichotomy in snakes. Bulletin of the Maryland Herpetological Society 23(4): 139–153.

Sönmez B, Sert M, Kayikçi S, Bedirci Ö, Özdilek ÞY (2017) A two-headed green sea turtle (*Chelonia mydas*) hatchling on Samandağ beach, Turkey. Russian Journal of Herpetology 24(2): 158–162. https://doi.org/10.30906/1026-2296-2019-24-2-158-162

Spadola F, Insacco, G (2009) Newborn dicephalic *Podarcis sicula*. Acta Herpetologica 4: 99–101. https://doi.org/10.1400/181616

Suzuki DG (2016) Two-headed mutants of the lamprey, a basal vertebrate. Zoological Letters 2(1): 1–6. https://doi.org/10.1186/s40851-016-0058-z

Tarkhnishvili D, Yanchukov A, Şahin MK, Gabelaia M, Murtskhvaladze M, Candan K, Galoyan E, Arakelyan M, Iankoshvili G, Kumlutaş Y, Ilgaz Ç, Matur F, Çolak F, Erdolu M, Kurdadze S, Barateli N, Anderson CL (2020) Genotypic similarities among the parthenogenetic *Darevskia* rock lizards with different hybrid origins. BMC Evolutionary Biology 20: 1–25. https://doi.org/10.1186/s12862-020-01690-9

Wagner CM, Rice PH, Pease AP (2013) First record of dicephalia in a bull shark *Carcharhinus leucas* (Chondrichthyes: Carcharhinidae) foetus from the Gulf of Mexico, USA. Journal of Fish Biology 82(4): 1419–1422. https://doi.org/10.1111/jfb.12064

Wallach V (2007) Axial bifurcation and duplication in snakes: Part I: A synopsis of authentic and anecdotal cases. Maryland Herpetological Society 43: 57–95.

Wallach V (2018) Axial bifurcation and duplication in snakes: Part VI: A 10-year update on authentic cases. Bulletin of Chicago Herpetological Society 53: 1–20.

Wise PA, Vickaryous MK, Russell AP (2009) An embryonic staging table for in-ovo development of *Eublepharis macularius*, the leopard gecko. The Anatomical Record: Advances in Integrative Anatomy and Evolutionary Biology: Advances in Integrative Anatomy and Evolutionary Biology 292(8): 1198–1212. https://doi.org/10.1002/ar.20945

Wu J, Staffenberg DA, Mulliken JB, Shanske AL (2002) Diprosopus: a unique case and review of the literature. Teratology 66: 282–287. https://doi.org/10.1002/tera.10102